



COMPARATIVE STUDY FOR RESPONSE TO *Cycas circinalis*-INDUCED TOXICITY IN LIVER, KIDNEY AND COLON OF RATS AND GUINEA PIGS.

*OLUDE, O. M. & OMOREGIE, F.O.

Department of Biochemistry, Faculty of Life Sciences, University of Benin, Benin City, Nigeria.

*Corresponding Author's E-mail: mujidat.olude@uniben.edu

ABSTRACT

This study evaluated the toxicological response of rats and guinea pigs to *Cycas* in feed. Ten rats and guinea pigs were randomly designated into two groups for each animal. The control groups were fed with a normal diet while the experimental groups were fed with the *Cycas*-containing feed for 6 weeks. The effect of the *Cycas* feed on the animals' liver, kidney, and colon were evaluated using biochemical and histological assays. The result of the experiment showed changes in body weight and tissue (liver, kidney, and colon) antioxidant levels. Additionally, the animals on the *Cycas* diet observed an increase in oxidative stress and lipid peroxidation. The histology result for both the rats and guinea pigs revealed that cycasin present in the plant is a potent colon carcinogen, it induced hyperplasia in the colon cells which is a great pointer towards abnormal cell division and hence cancer. We predicted that the plant via its induction of oxidative damage and depletion of tissue antioxidants could drive tissue toward tumorigenesis in both animals. There were significant changes between the ($p < 0.05$) values derived from the different animals. Guinea pigs were more susceptible to the negative effects of the cycasin.

Keywords: Antioxidants, Colon cancer, *Cycas*, Cycasin, Lipid peroxidation, Toxicological response

LICENSE: This article by African Journal of Health, Safety and Environment (AJHSE) is licensed and published under the Creative Commons Attribution License 4.0 International License, which permits unrestricted use, distribution, and reproduction in any medium, provided this article is duly cited.

COPYRIGHT: The Author(s) completely retain the copyright of this published article.

OPEN ACCESS: The Author(s) approves that this article remains permanently online in the open access (OA) model

QA: This Article is published in line with "COPE (Committee on Publication Ethics) and PIE (Publication Integrity & Ethics)".

INTRODUCTION

Cycas circinalis L, also known as "false or queen sago palm", is native to eastern and south-eastern Asia and is widely cultivated as an ornamental plant in most tropical and subtropical regions of the world (Sethi *et al.*, 2020). The species is one of the representatives of *Cycas*, the sole genus in the Cycadaceae family, comprising 113 species all of which occur in Australasia except for *C. thouarsii* (Calonje *et al.*, 2017).

C. circinalis is considered to be a nutritive and energizing tonic for people emaciated by famine or disease. Traditionally, starch derived from the powdered nuts of cycas palm was found to be a vital source of carbohydrates among Muduga and Kurumba natives in Kerala (Bino, 2010; Kumar and Kumar, 2017). The fleshy leaves serve as a vegetable, and roots as a source of sago (Lai *et al.*, 2003; Pecundo *et al.*, 2021). Other studies have communicated the importance of the plant in folklore medicine, with the male cones and seeds used as an aphrodisiac, central nervous system stimulant, antimicrobial, and antioxidant agent (Kumar and Kumar, 2017; Rahman *et al.*, 2020).

Reports have shown that leaves of *C. circinalis* are used in the treatment of diabetes mellitus, and are also known to exude moderate antibacterial activity (Arshad *et al.*, 2020; El-Seadawy *et al.*, 2023). Despite these outlined ethnomedicinal uses, well-established scientific information is also available on cycads' toxicity, including *C. circinalis*. Studies have shown that *C. circinalis* contains neurotoxins, carcinogens, and toxic chemicals capable of causing harm to the liver (Spencer *et al.*, 2015; Brown *et al.*, 2017). Cycasin is the primary toxic compound of the *Cycas* palm, which along with other azoxyglycosides is metabolized by plant and animal β -glucosidase to liberate the aglycone methylazoxymethanol (Brown *et al.*, 2017; Ekanayake *et al.*, 2021).

The presence of two active toxic derivatives in the cycas palm, methylazoxymethanol (MAM) and beta-N-methylamino-L-alanine (L-BMAA), which when metabolized yield formaldehyde, a known human carcinogen and neurotoxin (Spencer *et al.*, 2012). According to Ekanayake *et al.* (2021), kidney and colon carcinogenesis are associated with the short-term consumption of active ingredients found in cycas, whereas liver cancer requires a longer period of consumption of cycasin before it can develop. The authors also reported that a cycasin dose as small as 2.5 mg per day was found to induce liver tumours, small and large intestine tumours, abdominal tumour masses, as well as ascites. In addition, L-BMAA has been implicated in the pathogenesis of human neurological disorders such as lathyrism and amyotrophic lateral sclerosis (Kumar and Kumar, 2017).

In this current study, we established that feeding rats and guinea pigs with chows containing *C. circinalis* leaves induced oxidative stress, a condition where free radicals are generated in excessive amounts causing damage to cellular components and contributing to the development of diseases including neurodegenerative disorders and cancer. We also provided histological evidence of the damages caused by the plant and its mode of tumour initiation in animal tissues. This study aims to compare how different experimental animals (rats and guinea pigs) respond to toxicity when exposed to toxic materials. This study may help to throw light on a possible etiological relationship between the exposure of different people to toxic chemicals and the subsequent appearance or biochemical reactions that each exhibit.

MATERIALS AND METHODS

Plant sample collection and processing

C. circinalis was collected from a village near Benin City and authenticated and identified at the University of Benin's Plant Biology department. Following that, the plant leaves were washed, air-dried, and stored in a cool environment. After a while, the leaves turned brown and were ground into powder. The powder was stored in an airtight jar until it was needed.

Animals and Experimental Design

Ten Wistar rats and Ten Guinea pigs were randomly designated into four groups containing five animals each. The animals were kept in a 12-hour light/dark cycle room in various disinfected metal cages. The animals were acclimatized for two weeks before the experiment began and fed grower mash. Two groups were fed pure grower mash, and the other was fed the mash with 5% Cycas powder for six weeks. The groups and how their feeding were carried out are explained below.

Guinea Pigs: These guinea pigs were divided into two groups, the first group was fed with the normal feed (Grower Mash), twice daily for six (6) weeks. They served as our control group. While the other group was fed feed mixed with powdered Cycas plant leaves for the same duration. This group served as the experimental group, and the same protocol was used for both animal groups.

Rats: The Wistar rats were divided into two groups in the same fashion as the guinea pigs. The first group was fed with the normal feed (grower mash), twice daily for six (6) weeks and served as the control group. The other group was fed feed mixed with powdered Cycas plant leaves for the same duration and served as the experimental group. The same protocol was used on both animal groups.

Biochemical Assay

All biochemical parameters which included the Glutathione peroxidase activity, estimation of total protein concentration, catalase assay, and superoxide dismutase assay were determined using standard procedures with the right kits, purchased from Randox Laboratories, United Kingdom. Glutathione peroxidase activity was evaluated, using the Chance and Maehly, 1995 method. The estimation of total protein concentration was determined using the Biuret method (Henry *et al.*, 1957). The catalase activity was determined using the method proposed by Cohen *et al.*, 1970, while the superoxide dismutase assay was evaluated using the method of Mishra and Fridovich (1972).

Histopathological evaluation

This was carried out according to the method described by Kiernan, 2008. A portion of the colon from the different experimental animals at the point of sacrifice was fixed in 10% buffered formalin, dehydrated in graded alcohol and embedded in paraffin. Fine sections were obtained, mounted on glass slides and counter-

stained with hematoxylin-eosin for light microscopic examination. The slides were coded and examined by a histopathologist.

Statistical Analysis

The results obtained were expressed as mean and SEM and P-values of less than 0.05 were considered statistically significant. Statistical analysis was performed by one-way analysis of variance (ANOVA) followed by a post-hoc least square difference (LSD) for individual groups using the SPSS 16 statistical software.

RESULTS

The biochemical results of the test carried out are hereby expressed below. From the data below, the change in body weight (figure 1) in the guinea pigs fed with *C. circinalis* is lower when compared to the control group (normal feed). However, the reverse is the case with the rats. Also, a significant decrease ($P < 0.05$) in antioxidant activity (catalase (CAT), SOD, and GPx) was observed in the colon of cycas feed animals. This pattern was repeated in the liver and kidney of animals fed with *C. circinalis* with the exceptions of the superoxide dismutase (SOD) activity in the liver and the glutathione peroxidase (GPx) activity in both the liver and kidney where the difference is not significant. A significant increase ($P < 0.05$) in malondialdehyde (MDA) and glucose 6 phosphate dehydrogenase (G6PD) concentration was also recorded across all tissues while the total protein concentration was fairly maintained in both the colon and the liver.

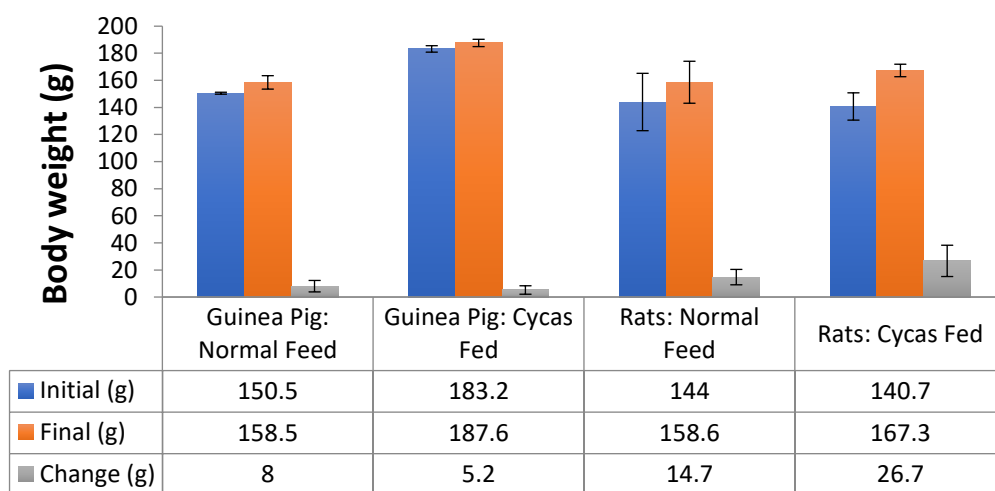


Figure 1: Data showing the effect of *C. circinalis* feed on the body weight of animals.

Values are expressed as Mean \pm SD; $n = 5$

Table 1: Data showing the effect of *C. circinalis* feed on the colon of test animals.

GROUPS		CAT (Units*10 ³ /g)	SOD (Units/g)	GPx (Units/g)	MDA (Units*10 ³ /g)	G6PD (Units/mg)	Total protein (mg/dl)
Guinea pig	Normal Feed	30.2 ± 7.62 ^a	2.65 ± 0.83 ^a	4.67 ± 1.01 ^a	2.13 ± 0.04 ^a	0.08 ± 0.01 ^a	1.89 ± 0.54 ^{ab}
	Cycas Feed	17.05 ± 0.92 ^b	0.99 ± 0.28 ^a	2.63 ± 1.24 ^b	6.14 ± 0.98 ^b	0.26 ± 0.01 ^b	0.98 ± 0.17 ^b
Rat	Normal Feed	27.8 ± 11.11 ^a	13.62 ± 4.24 ^b	5.83 ± 2.67 ^a	0.65 ± 0.19 ^c	0.11 ± 0.04 ^a	1.04 ± 0.21 ^b
	Cycas Feed	15.0 ± 0.53 ^b	4.49 ± 2.64 ^a	2.33 ± 1.01 ^b	2.44 ± 0.16 ^a	0.14 ± 0.04 ^c	0.76 ± 0.04 ^b

Values are expressed as Mean ± SD; n = 5

Values with different superscripts are significantly different from each other P < 0.05

Table 2: Data showing the effect of *C. circinalis* feed on the liver of test animals.

GROUPS		CAT (Units*10 ³ /g)	SOD (Units/g)	GPx (Units/g)	MDA (Units*10 ³ /g)	G6PD (Units/mg)	Total protein (mg/dl)
Guinea pig	Normal Feed	28.10 ± 3.44 ^a	2.42 ± 1.36 ^a	7.88 ± 3.71 ^a	1.04 ± 0.30 ^a	0.10 ± 0.03 ^a	1.78 ± 0.44 ^a
	Cycas Feed	14.50 ± 0.50 ^b	1.59 ± 0.56 ^a	4.32 ± 0.66 ^a	5.65 ± 1.30 ^b	0.42 ± 0.04 ^b	0.68 ± 0.19 ^a
Rat	Normal Feed	39.6 ± 5.99 ^a	3.70 ± 1.60 ^a	5.25 ± 1.75 ^a	1.07 ± 0.30 ^a	0.20 ± 0.05 ^c	1.12 ± 0.38 ^a
	Cycas Feed	14.80 ± 0.85 ^b	4.37 ± 2.76 ^a	4.08 ± 2.67 ^a	2.21 ± 0.23 ^{ab}	0.27 ± 0.08 ^c	0.84 ± 0.09 ^a

Values are expressed as Mean ± SD; n = 5

Values with different superscripts are significantly different from each other P < 0.05

Table 3: Data showing the effect of *C. circinalis* feed on the kidneys of test animals.

GROUPS		CAT (Units*10 ³ /g)	SOD (Units/g)	GPx (Units/g)	MDA (Units*10 ³ /g)
Guinea pig	Normal Feed	32.5 ± 7.21 ^a	22.09 ± 8.48 ^a	5.25 ± 2.47 ^a	1.47 ± 0.03 ^a
	Cycas Feed	15.2 ± 1.50 ^b	5.16 ± 1.68 ^b	4.67 ± 2.67 ^a	5.83 ± 0.49 ^b
Rat	Normal Feed	32.3 ± 6.93 ^a	7.94 ± 3.46 ^b	5.25 ± 3.03 ^a	0.78 ± 0.04 ^a
	Cycas Feed	14.9 ± 0.78 ^b	1.32 ± 0.61 ^c	2.33 ± 1.01 ^a	2.73 ± 0.79 ^c

Values are expressed as Mean ± SD; n = 5

Values with different superscripts are significantly different from each other $P < 0.05$

Histology result

The photomicrograph of the colon tissues of the cycas-fed animals is shown in plates 1 – 4. The active ingredients present in *C. circinalis*. The carcinogen caused necrosis, hyperplasia and aberrant architecture in the colon of the animals with the guinea pigs more affected.

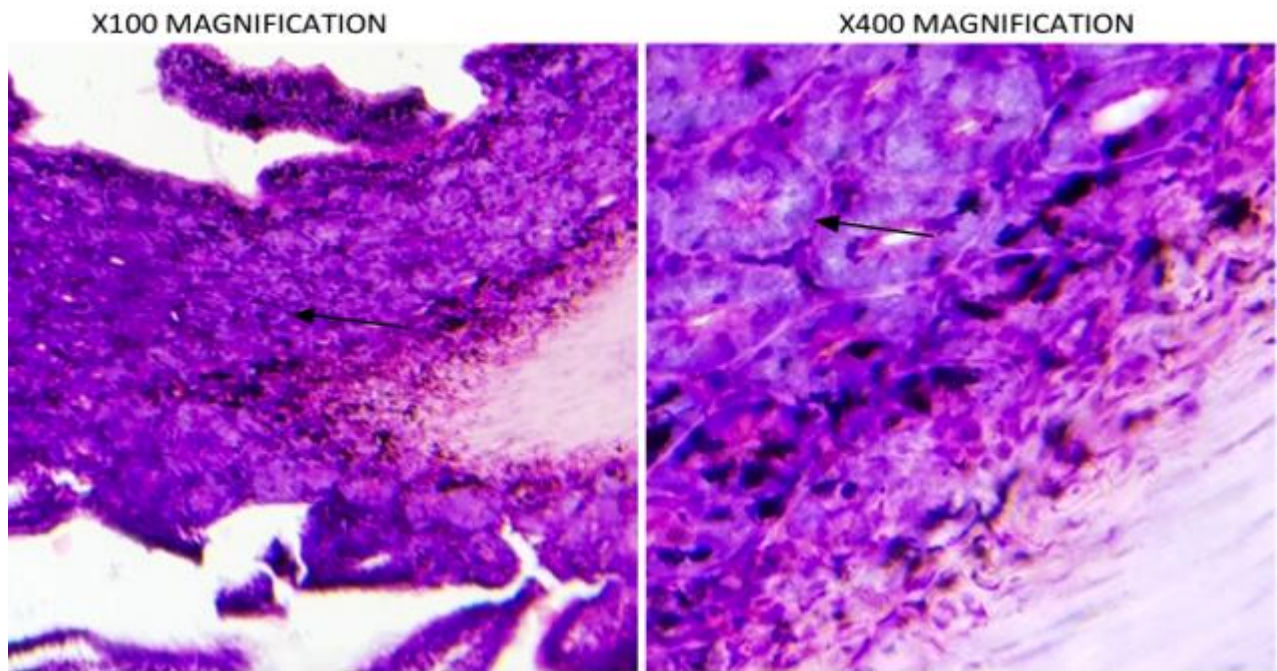


Plate 1: Photomicrograph of the colon of cycas-fed rats reveals distorted lamina propria lined by visible columnar epithelium and crypt of lieberkuhn at low power (×100 magnification) and bound by dense muscularis mucosae shows erosion at both low and high-power magnifications. The higher magnification also showed marked glandular hyperplasia.

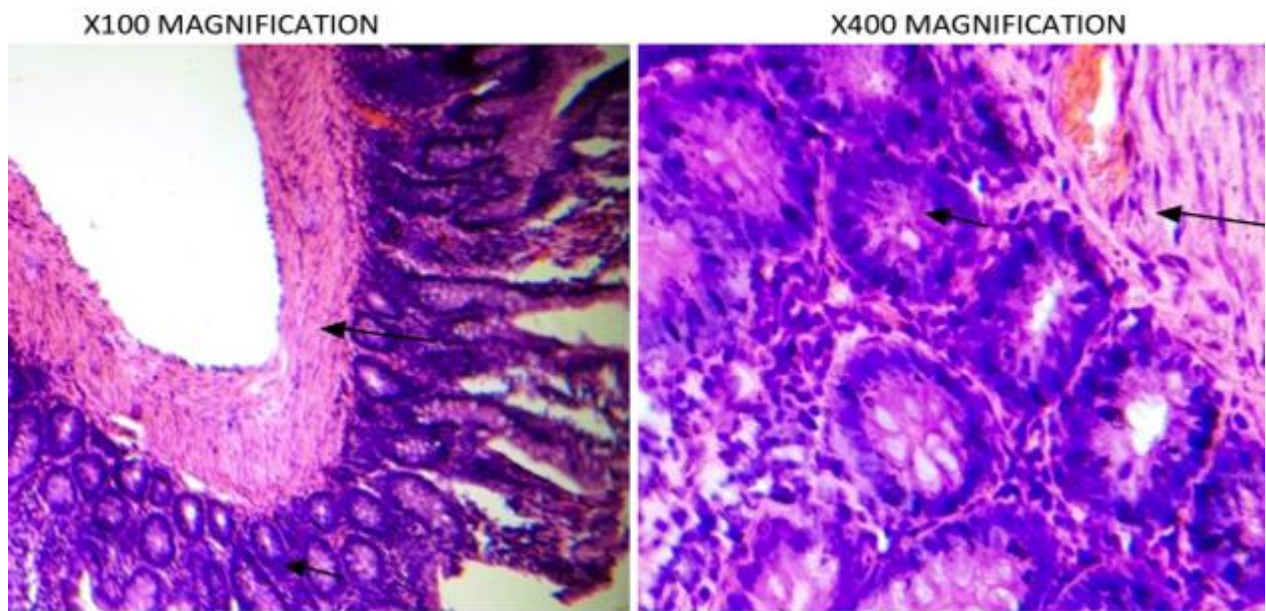


Plate 2: Photomicrograph of the colon of cycas-fed rats reveals distorted lamina propria lined by visible columnar epithelium and crypt of lieberkuhn at low power ($\times 100$ magnification) and bound by dense muscularis mucosae shows erosion at both low and high-power magnifications. The higher magnification also showed pyknotic nucleus lines side by side.

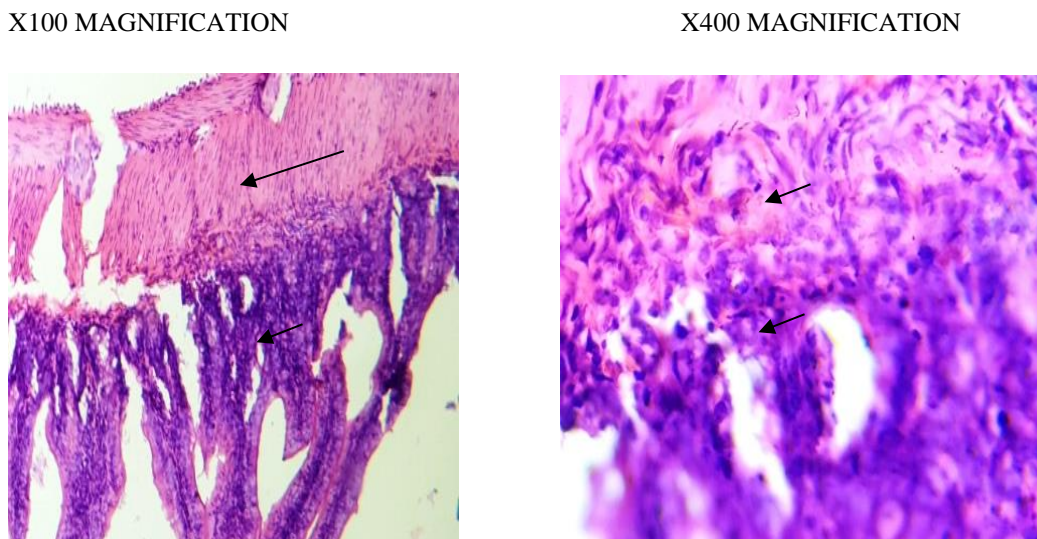


Plate 3: Photomicrograph of the colon of cycas-fed guinea pigs. Colon histology reveals mucosal oedema with abnormal mitosis and marked infiltrates of inflammatory cells. The histology appears distorted.

X100 MAGNIFICATION

X400 MAGNIFICATION

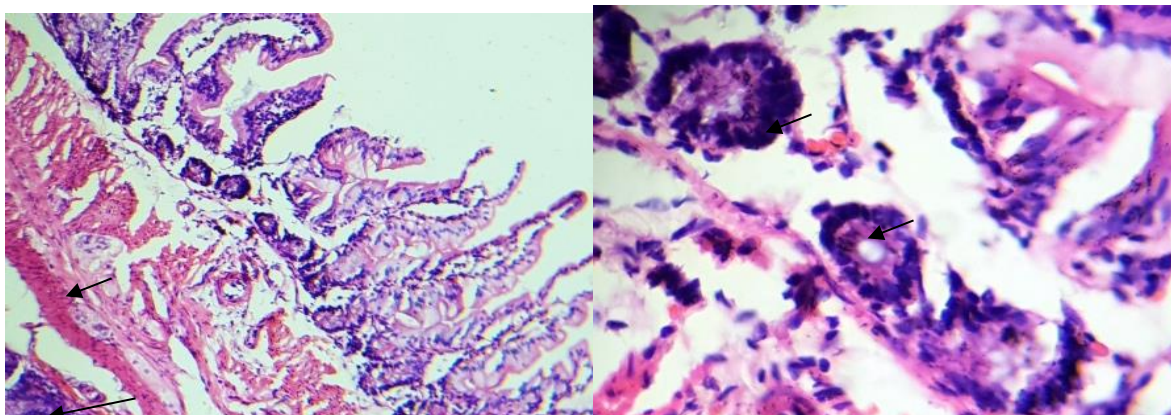


Plate 4: Photomicrograph of the colon of cycas-fed guinea pigs. Colon histology reveals muscularis mucosae at low and high-power magnifications with deeply stained columnar epithelium with marked nuclear atypia and prominent goblet cells at higher magnification.

DISCUSSION

Methyl azoxymethanol is the aglycone of cycasin present in *Cycas circinalis*; this compound is formed from the hydrolysis of the β -glucoside bond of cycasin by intestinal bacteria. The active metabolite produced thereafter is a carcinogen that induces colorectal cancer in animals (Kobets *et al.*, 2022; Okolie *et al.*, 2013). During carcinogenesis, several mechanisms disrupt normal physiological metabolism: increased glycolysis, mitochondrial defects, insensitivity to anti-growth signals, evasion of apoptosis, activation of proto-oncogenes, cell cycle deregulation, and abnormal expression of metabolic enzymes (Chrysanthakopoulos and Vryzaki, 2023).

This study was undertaken to evaluate the effect of *C. circinalis* -induced change in the colon, liver, and kidney of rats and guinea pigs. The result obtained showed an increase in oxidative stress and lipid peroxidation as observed in the significant decrease in the activities of tissue antioxidant enzymes (catalase, glutathione peroxidase, and superoxide dismutase) and the increase in malondialdehyde levels. The overproduction of free radicals and their effect on polyunsaturated fatty acids (PUFA) causes lipid peroxidation in membranes, which is a risk factor for tumor formation (Gunes *et al.*, 2022). Cycasin and its aglycone methyl azoxymethanol cause lipid peroxidation; they interact covalently with DNA, forming adducts and causing DNA breakage and cross-linkage (Saeed *et al.*, 2022). This might be the reason why the MDA level of rats exposed to *Cycas* was elevated.

Histological evidence provided in the result above further corroborates these findings. Glandular hyperplasia, distorted lamina propria and oedema are common features of early carcinogenesis (Bera *et al.*, 2018). These were observed in the histology results of cycas-fed animals. Most cancers are usually associated with loss of tissue protein (Akinwunmi *et al.*, 2023). Superoxide dismutase (SOD) is a class of metalloprotein that catalyze the dismutation of superoxide radicals to oxygen and hydrogen peroxide. SOD provides a vital defense mechanism against the formation of deleterious oxygen species and protects cells from oxidative

damage. Eriyamremu *et al.* (2007) reported that the presence of antinutrients in Cycas antagonizes SOD activity, hence a reduction in the level of this enzyme. A similar trend was observed in this study. Cycas-fed animals had a reduced level of SOD activity when compared with the control ($P < 0.05$). Catalase is an enzymatic antioxidant that catalyzes the decomposition of hydrogen peroxide to oxygen and water, thereby curtailing oxidative damage and stress produced during the harmful oxidation process (Lolodi and Eriyamremu, 2013; Yang *et al.*, 2023). Since catalase is a key enzyme for the resistance to oxidative stress, therefore a decrease in catalase activity suggests that they are generally downregulated in tumour tissues compared with normal cells. Same scenario was seen in this experiment, there was a significant decrease in CAT activity of cycas-fed animals compared to controls ($P < 0.05$).

Glutathione peroxidase (GPx) is a ubiquitously expressed selenium-dependent enzyme that protects cells against oxidative damage by reducing hydrogen peroxide and a wide range of organic peroxide (Mohideen *et al.*, 2023; Pei *et al.*, 2023). From the results, GPx activity was decreased in Wistar Rats and Guinea Pigs fed with Cycas, indicating that its anti-oxidant activity was depleted. Hence, driving the cells towards oxidative damage and tumor formation. Glucose 6 Phosphate Dehydrogenase (G6PD) has been revealed to be involved in apoptosis and cell proliferation (Jiang *et al.*, 2013). It also controls the Pentose Phosphate Pathway and has been appreciated largely for its role as a provider of reducing power (NADPH) and ribose phosphate to the cell for the maintenance of redox balance and biosynthesis of nucleotides and lipids (Wang *et al.*, 2023).

Aberrant activation of G6PD leads to enhanced cell proliferation and adaptation in various tumours. It is also known that elevated activity of G6PD is common in multiple tumours, including leukemia, gastrointestinal cancers, renal cell carcinomas, colon cancers, prostate and liver cancer (Hu *et al.*, 2013; Pes *et al.*, 2019; Zheng *et al.*, 2023).

Comparing the data of the rats and guinea pigs; the colon (Table 1) antioxidants status of the two animals differs. There were slight changes in the catalase (CAT), glutathione peroxidase (GPx), glucose 6 phosphate dehydrogenase activities (G6PD) and protein levels of the control group of both rat and guinea pigs when compared, though statistically significant. This same trend was observed in the enzyme activity of the cycas-fed groups. Superoxide dismutase (SOD) activity differs statistically between the animals. The rats showed higher activity of SOD compared to guinea pigs. This was also consistent in the enzyme activity of the cycas fed. The malondialdehyde (MDA) level of the control rats was significantly lower compared to that of the control group of guinea pigs while the MDA level of cycas-fed guinea pigs was significantly higher compared to the cycas-fed rats.

The liver (Table 2) CAT activities of the control test animals were statistically different from each other, comparing the effect of the carcinogen on CAT activities of the two different animals, there were no differences. SOD activities of the control group of the two animals differ slightly but a significant increase was seen in the activities of cycas-fed rats compared to cycas-fed guinea pigs. GPx activities of the two different cycas-fed animals were not statistically significant when compared. MDA and total protein levels of the control group of the two animals were not statistically significantly different when compared but the liver MDA levels of the cycas-fed guinea pigs were significantly increased compared to the cycas-fed rats.

The kidney antioxidants of the different animals as shown in Table 3. CAT activities of both the control and the carcinogen-treated groups of both rats and guinea pigs were not statistically different. There was a huge gap in the SOD activities between the two animals. Guinea pigs expressed more SOD activities compared to rats. GPx activities were the same in the control group of the two animals but the cycas-fed guinea pigs had an increased level of this enzyme compared to the cycas-fed rats. Cycas-fed Guinea pigs expressed more MDA levels compared to cycas-fed rats. Comparing the histology (Plate 1 - 4) results of the two different animals, the architecture of cycas-fed guinea pigs' colons was more distorted compared to the cycas-fed rats' colons.

CONCLUSION

This study shows clearly that the ways animals respond to toxins or toxicants differ. Guinea pigs are more prone to develop cancer if exposed to toxicants that contain the active compounds present in cycas: methylazoxymethanol, beta-N-methylamino-L-alanine, and formaldehyde. For further studies, it is recommended that other parameters such as lactate dehydrogenase, tumor markers, etc. be assayed to give a clearer picture of the toxic response of rats and guinea pigs to *C. circinalis*.

CONFLICTS OF INTEREST: The authors declare that they have no conflict of interest.

REFERENCES

- Arshad, M., Chaudhary, A.R., Mumtaz, M.W., Raza, SA, Ahmad, M. and Mukhtar, H. (2020). Polyphenol fingerprinting and hypoglycemic attributes of optimized *Cycas circinalis* leaf extracts. *Journal of the Science of Food and Agriculture*, DOI: 10.1002/jsfa.10771.
- Bera, S., Das, B., De, A. and Samanta A. (2018). Preventive effect of *cycas revoluta* in 1,2-dimethylhydrazine-induced colon cancer in wistar rat model. *Asian Journal of Pharmaceutical and Clinical Research*, **11**(5):120-123.
- Bino S. (2010). Wild edible plants used by the tribals in Pathanamthitta District, Kerala. *Indian Journal of Traditional Knowledge* **9**(2): 309-312.
- Brown, D.L., Van Wettene A.J, and Cullen J. M. (2017), eds: Zachary, J. F, McGavin M. D; Hepatobiliary System and Exocrine Pancreas. *Pathologic Basis of Veterinary Diseases*. 6th ed. Elsevier. Saint Louis, MO, USA. pp. 412-470.
- Chance, B. and Maehly, A.C. (1995). Assay of Catalase and Peroxidase. *Methods in Enzymology*, **2**:764-775.
- Chrysanthakopoulos, N. A. and Vryzaki, E. (2023). The Special Role of JAK/STAT, and Notch Signaling Pathways in Cancer Pathogenesis. *Journal of Case Reports and Medical History* **3**(7): doi <https://doi.org/10.54289/JCRMH2300135>
- El-Seadawy, H. M., El-Seoud, K. A. A., El-Aasr, M. and Ragab, A.E. (2023). Cycadaceae: An Important Source for Biflavonoids and Various Pharmacological Effects of Different Cycas Species. *Journal of Advanced Medicine and Pharmaceutical Research*, **4**:35-41
- Eriyamremu, G.E., Asagba, S.O, Uanseoje, S.O., Omoregie, S.E. and Omofoma, C.O. (2007). Colonic lipid peroxidation, nuclear membrane ATPase and stress enzymes in rats fed a Nigerian-like Diet and Cycas. *Journal of Biology Science*, **7**: 526-631.

- Gunes, S., He, Z., Tsoukou, E., Ng, S. W., Boehm, D., Lopes, B. P., Bourke, P., Malone, R., Cullen, P. J., Wang, W. and Curtin, J. (2022). Cell death induced in glioblastoma cells by Plasma-Activated Liquids (PAL) is primarily mediated by membrane lipid peroxidation and not ROS influx. *PLoS ONE* **17**(9): e0274524. <https://doi.org/10.1371/journal.pone.0274524>
- Henry, R. I., Charles, S. and Sam, B. (1957). Interferences with biuret methods for serum proteins use of Benedict's qualitative glucose reagent as a biuret reagent. *Analytical Chemistry*, **29**(10):1491–1495
- Hu, T., Zhang, C., Tang, Q., Su, Y., Li, B., Chen, L., Zhang, Z., Cai, T. and Zhu, Y. (2013). Variant G6PD levels promote tumor cell proliferation or apoptosis via the STAT3/5 pathway in the human melanoma xenograft mouse model. *Biomedicine Central Cancer*, **13**(251):1-11.
- Jiang, P., Du, W. and Yang, X. (2013). A critical role of glucose-6-phosphate dehydrogenase in TAp73-mediated cell proliferation. *Cell Cycle*, **12**((24): 3720–3726;
- Julian, G., Antonio, M., Xavier, A., Lluís, M.M. and Mounir, T. (2014) Lipid Peroxidation in Membranes: The Peroxyl Radical Does Not “Float. *Journal of Physical Chemistry*, **5**(10):1653–1658.
- Kobets, T., Smith, B.P.C. and Williams, G.M. (2022). Food-Borne Chemical Carcinogens and the Evidence for Human Cancer Risk. *Foods*, <https://doi.org/10.3390/foods11182828>.
- Kumar, S.B. and Kumar, V.J. (2017). Antimicrobial and Antioxidant Activity of *Cycas circinalis* L. and *Ionidium suffruticosum* ging. *Innovare Journal of Medical Science*, **5**(1): 31-33.
- Lal, J. J. (2003). Sago palm. In: Caballero B. (ed). *Encyclopedia of Food Sciences and Nutrition*. Oxford: Academic Press pp. 5035-5039.
- Lolodi, O. and Eriyamremu, G.E. (2013). Effect of methanolic extract of *Vernonia amygdalina* (common bitter leaf) on lipid peroxidation and antioxidant enzymes in rats exposed to cycasin. *Pakistan Journal of Biological Science*, **16**(13):642-646.
- Misra, H.P. and Fridovich I. (1972). The role of superoxide anion in the auto-oxidation of epinephrine and a simple assay of superoxide dismutase. *Journal of Biological Chemistry*, **247**(12): 3170–3175.
- Mohideen, K., Jeddy, N., Krithika, C., Faizee, S. H., Dhungel, S. and Ghosh, S. (2023). Assessment of glutathione peroxidase enzyme response and total antioxidant status in oral cancer – Systematic review and meta-analysis. *Cancer Reports*. **6**:e1842. <https://doi.org/10.1002/cnr2.1842>
- Okolie, N.P, Agu, K. and Eze, G.I. (2013). Protective effect of ethanolic leaf extract of *Annona muricata* Linn on some early events in Cycas-induced colorectal carcinogenesis in rats. *Journal of Pharmaceutical and Scientific Innovation*, **2**(4):14-21.
- Pecundo, M.H., Chang, A.C.G., Chen, T., Cruz, T.E.E., Ren, H. and Li, N. (2021). Full-Length 16S rRNA and ITS Gene Sequencing Revealed Rich Microbial Flora in Roots of *Cycas* spp. in China. *Evolutionary Bioinformatics*, **17**: 1–16
- Pei, J., Pan, X., Wei, G. and Hua, Y. (2023). Research progress of glutathione peroxidase family (GPX) in redoxiation. *Frontiers in Pharmacology*, **14**:1147414. doi: 10.3389/fphar.2023.1147414
- Pes, G. M., Errigo, A., Soro, S., Longo, N. P. and Dore, M. P. (2019). Glucose-6-phosphate dehydrogenase deficiency reduces susceptibility to cancer of endodermal origin, *Acta Oncologica*, **58**(9):1205-1211.
- Rahman, J., Tareq, A.M., Hossain, M.M., Sakib, S.A., Islam, M.N., Ali, M.H., Uddin, A.B.M.N., Hoque, M., Nasrin, M.S., Emran, T.B., Capasso, R., Reza, A.S.M.A. and Simal-Gandara, J. (2020). Biological evaluation, dft calculations and molecular docking studies on the antidepressant and cytotoxicity activities of cycas pectinata buch.-ham.compounds. *Pharmaceuticals*, **13**:232; doi:10.3390/ph13090232

- Saeed, P. M., Shoaib, A., Kandimalla, R., Javed, S., Almatroudi, A., Gupta, R. and Aqil, F. (2022). Microbe-based therapies for colorectal cancer: advantages and limitations. *Seminars in Cancer Biology*, **86**(3):652-665
- Senadheera, S., Senevirathna, R. and Ekanayake, S. (2021). Liver Toxicity of Raw and Processed *Cycas circinalis* (Madu) Seed Flour: An Animal Study. *International Journal of Multidisciplinary Studies*, **8**(1):1-10.
- Sethi, P., Gupta, H., Ellakiya. and Kumar, B. (2020). Histology of a xerophytic leaflet: *Cycas circinalis* and *cycas revoluta* (cycadaceae). *Chemistry & Material Sciences Research Journal*, **2**(1):6-14,
- Spencer, P.S., Fry, R.C. and Kisby, G.E. (2012). Unraveling 50-year-old clues linking neurodegeneration and cancer to cycad toxins: are microRNAs common mediators? *Frontiers in Genetics*, **3**(192): 1-17.
- Spencer, P.S., Garner, C. E, Palmer, V.S. and Kisby, G.E., eds: Aschner, M., Costa, L. G. (2015). Environmental factors in neurodevelopmental and neurodegenerative disorders. Academic Press. pp 211-252.
- Wang, C., Yu, C., Chang, H., Song, J., Zhang, S., Zhao, J., Wang, J., Wang, T., Qi, Q. and Shan, C. (2023). Glucose-6-phosphate dehydrogenase: a therapeutic target for ovarian cancer. *Expert Opinion on Therapeutic Targets*, **27**(8): 733-743, DOI: [10.1080/14728222.2023.2247558](https://doi.org/10.1080/14728222.2023.2247558)
- Yang, T., Peng, Q., Lin, H. and Xi, D. (2023). Alpha-momorcharin preserves catalase activity to inhibit viral infection by disrupting the 2b–CAT interaction in *Solanum lycopersicum*. *Molecular Plant Pathology*, **24**:107–122.
- Zheng, P., Pan, H., Zhou, X., Qiu, X., Hu, J., Qin, Z. and Wang, T. (2023). Glucose 6 phosphatase dehydrogenase (G6PD): a novel diagnosis marker related to gastrointestinal cancers. *American Journal of Translational Research*, **15**(4):2304-2328