

POSSIBLE THERAPEUTIC EFFECTS OF *Dioscorea alata* (WATER YAM) EXTRACT ON TRAMADOL-TREATED WISTAR ALBINO RATS' GASTROINTESTINAL SYSTEM.

^{*1}OMORODION, N.T. & ²NWABANA, B.K.

^{*1}Department of Medical Laboratory Sciences, School of Basic Medical Sciences, College of Medicine University of Benin, Benin City, Nigeria.

²River state College of Health Sciences and Management Technology, Port-Harcourt, River State, Nigeria.

Corresponding Author's E-mail: terry.omorodion@uniben.edu; Orcid ID: <https://orcid.org/0000-0002-5500-5293>

Phone: [+2348136742270](tel:+2348136742270)

ABSTRACT

It has long been recognised that *Dioscorea alata* (water yam), provides therapeutic benefits. The commonly used analgesic tramadol has been linked to negative effects on the gastrointestinal tract. The researchers looked at how *Dioscorea alata* (water yam) extract might help the digestive systems of albino rats that had been given tramadol beforehand. A controlled experimental setup was used with twenty-five albino rats split up into five groups (control, negative, positive, and counter groups). Histological investigations assessed the structural and functional changes to the gastrointestinal tissues. Cell damage, oxidative stress, and tissue inflammation were among the parameters that were assessed. The statistical programme for social sciences, or SPSS version 20, was used to analyse the data that was produced. Group 3 rats' body and organ (stomach) weights were significantly lower than those of Group 1. This investigation showed that tramadol inflamed the gastrointestinal tracts of the rats in group 3. On the other hand, it was shown that *Dioscorea alata* helped to reduce some of these inflammations and changes in tissue architecture. The gastro-intestinal tract of rats in group 3 that were only given *Dioscorea alata* had some mild inflammatory cells. This study suggests that the extract from *Dioscorea alata* may lessen tramadol-induced gastrointestinal tissue damage in albino Wistar rats. It is recommended that human subjects be used for further research in order to clarify the underlying processes of these effects, evaluate dose concerns, and analyse the long-term effects of such treatment.

Keywords: *Dioscorea alata*, gastrointestinal tract, tramadol treatment, Wistar albino, Water yam

LICENSE: This article by African Journal of Health, Safety and Environment (AJHSE) is licensed and published under the Creative Commons Attribution License 4.0 International License, which permits unrestricted use, distribution, and reproduction in any medium, provided this article is duly cited.

COPYRIGHT: The Author(s) completely retain the copyright of this published article.

OPEN ACCESS: The Author(s) approves that this article remains permanently online in the open access (OA) model

QA: This Article is published in line with "COPE (Committee on Publication Ethics) and PIE (Publication Integrity & Ethics)".

INTRODUCTION

Many species in the family *Dioscoreaceae* and genus *Dioscorea* are known by their common name, yam. According to Fu *et al.* (2005), this crop is a staple of great importance in West Africa and has made a substantial contribution to the population's overall nutritional intake over time (Fu *et al.*, 2005). A few species in the genus are recognised to be highly nutritious, containing vitamins B6 and C, potassium, manganese, and other elements. It is the third most significant tropical root and tuber crop, behind sweet potatoes and cassava (Bhandari *et al.*, 2003).

According to Nwaoguikpe (2009), thiocyanate, which is found in African yams (*Dioscorea species*), may offer some protection against sickle cell anaemia. Some decades ago, it was discovered that the tubers of some wild species of *Dioscorea*, like *Dioscorea nipponica* (also known as the Japanese yam or yamaimo), contained diosgenin (Nwaoguikpe, 2009). This steroid, sapogenin, was extracted and used to make cortisone, progesterone, and other steroid products for commercial use (Maithili *et al.*, 2011). A number of illnesses, including arthritis, cancer, diabetes, gastrointestinal issues, high cholesterol, and inflammation, have reportedly been treated or prevented with wild yam tubers, according to reports from the Memorial Sloan-Kettering Cancer Centre (Asumugha *et al.*, 2009). The yam's mucilaginous characteristic sets it apart from other yams, making it less commonly used in cooking (Asumugha *et al.*, 2009). Yoruba people use it to prepare dishes like ikokore, a type of water yam porridge, and ojojo, which are fried balls of grated water yam. Igbos also use it to make Mbogiri. Ewura is the Yoruba word for water yam. Water yam is loaded with minerals, including copper, iron, phosphorus, calcium, potassium, vitamin A, and several B vitamins; it also contains the antioxidant-rich vitamins C and E, which control blood sugar, suggesting they are helpful for people with diabetes (Wireko-Manu *et al.*, 2013).

According to NIDDK (2017), the gastrointestinal tract, also referred to as the GI tract or digestive tract, is what makes up the digestive system. From the mouth to the anus, the GI tract is a lengthy, twisted tube made up of several hollow organs (NIDDK, 2017). The hollow organs of the GI tract are the mouth, the oesophagus, the gastrointestinal tract, small, large, and anus. The pancreas, liver, and gallbladder are the digestive system's three solid organs (NIDDK, 2017). Three portions make up the intestines. The first part is known as the duodenum. According to NIDDK (2017), the jejunum is in the middle and the ileum is at the end. The sections that make up the large intestine are the colon, rectum, appendix, and cecum. The appendix is a pouch that resembles fingers and is attached to the cecum. The large intestine's first section is referred to as the cecum. The colon is the next. The large intestine terminates in the abdominal cavity (NIDDK, 2017).

According to Owoade *et al.* (2019), tramadol is a synthetic, centrally acting analgesic that has effects ten times less potent than morphine and comparable to codeine. Tramadol is used to treat a variety of conditions, most notably moderate-to-severe acute or chronic pain (Owoade *et al.*, 2019). Three mechanisms underlie the analgesic effect of tramadol: mu-opioid binding, nor-epinephrine, and serotonin reuptake inhibition (Owoade *et al.*, 2019). A common analgesic drug (tramadol) has been linked to negative gastrointestinal side effects such as inflammation, cellular damage, and stomach ulcers when used over an extended period of time (Tørring *et al.*, 2008). *Dioscorea alata* has demonstrated promising qualities in traditional medicine, and its investigation is a result of the hunt for natural medicines with possible therapeutic benefits for the GI tissues (Owoade *et al.*, 2019). *Dioscorea alata*'s precise effects on the gastrointestinal tissues of animals who have previously received tramadol treatment, however, have not been thoroughly examined and need more research.

As a substitute, herbal medicine, this study looks into the potential of *Dioscorea alata* as an herbal remedy for tramadol-related gastrointestinal harm. If *Dioscorea alata* shows promise in this investigation, it might aid in the creation of complementary methods or other alternatives for treating patients' negative Tramadol side effects. Comprehending science and how it applies to medicine: This study's findings may indicate that *Dioscorea alata* could lessen the gastrointestinal damage that tramadol induces. With this information, physicians may be able to treat patients more effectively by preventing or reducing the negative impacts of Tramadol on the gastrointestinal system through the use of supplements containing *Dioscorea alata* or other related treatments. The purpose of this study was to examine the potential medicinal benefits of an extract derived from the peel of *Dioscorea alata* on the digestive system of albino Wistar rats after they had received tramadol treatment.

MATERIALS AND METHODS

Location and Duration of the Study

In the Histopathology Sub-Departmental Laboratory of the Department of Medical Laboratory Science, School of Basic Medical Sciences, College of Medical Sciences, University of Benin, Benin City, the current inquiry was carried out. The investigation was undertaken from January 31, 2023, until June 30, 2023.

Reagents and Chemical

Xylene, ethanol, dispersion plasticizer, 1% acid-alcohol, hematoxylin dye, eosin dye, 10% neutral buffered formalin, and ordinary saline were some of the chemicals that were used in the experiment. It is worth noting that all chemicals were distilled prior to their use.

Tramadol procurement

Hundred (100mg) of tramadol was purchased from Thelver Pharmacy, located at Isihor, Lagos-Benin express way, in Benin City with an ethical approval.

Equipment and apparatus

Plastic cages, cotton wool, gauze, husks, an analytical weighing balance, and dissection tools (dissection board, dissection kit) Panoramic glasses: Slides, universal containers, conical flask, cover slip, measuring cylinder, 5 ml syringes, Materials for processing tissue: Hestion ATP7000 tissue processor (Germany); Leuckhart moulds; Embedding Machine (Germany); Digital Rotary Microtome (Germany); Water Bath (Gallenkamp); Hot Plate; Muslin Cloth; Staining Rack; Soxhlet Extractor; Forceps and Swift (R) Binocular Soxhlet Extractor; Microscope (Olympus England); Digital Electronic Balance (Italy; sensitivity = 0.001 g).

Plant-Based Materials

Dioscorea alata was acquired at Benin City's Ekiosa Market. Prof. Henry A. Akinnibosun identified and validated the plant at the Department of Plant Biology and Biotechnology, Faculty of Life Science, University of Benin. The departmental herbarium received the sample plant and assigned it a voucher number (UBH-D604) so that it could be cross-referenced and used to access any updates to previous research.

Preparing plant material

Dioscorea alata peels into small pieces, which accelerates the drying process. Before drying, a thorough cleaning with tap water was performed. It became dry at 40 °C. Before utilising a Blendtec electric blender with a 3000-watt power output to grind it into a fine, uniform powder, it was thoroughly dried.

Extraction

Using clamps and stands, a rig was constructed to support the extraction tool. A round-bottom flask was filled with a Soxhlet extractor and condenser on an isomantle, and the solvent was 250 ml of ethanol. A peel of the crushed plant material, *Dioscorea alata*, was put into the Soxhlet extractor's thimble. The isomantle's heat causes the solvent to evaporate as it passes through the device and enters the condenser. The condensation then finds its way into the reservoir holding the thimble. The cycle starts when the solvent level reaches the syphon and drips back into the flask. Over three days, the extraction procedure took at least sixteen hours to complete.

Freeze Drying

The ethanol was removed and sent to the University of Benin's research lab. An SCIENTZ-12N was used to freeze-dry the extracted ethanol using a laboratory lyophilizer. The plant extracts could be supplied in a frozen, semisolid state.

Acute Toxicity

The median lethal dose (LD50) of the peeled *Dioscorea alata* extract was found so that the right dose could be used to test its healing properties (Maithili et al., 2011). Five (5) groups of two rats each were used to provide an extract dose, with the range being 2000, 1000, 500, 300, and 200 mg per kilogramme of body weight. The animals were observed for adverse consequences, such as death, for a duration of 48 hours.

Experimental Animals

Twenty-five (25) Wistar rats, each weighing between 120 and 180 g, were purchased from the Department of Anatomy Animal House, University of Benin, and housed for a two-week period to allow for acclimatization. The five groups (I to V) of experimental rats were kept in plastic cages with wire gauges to provide proper ventilation, food for meals, and water available at all times. Before the experiment began, the room's temperature and relative humidity were adjusted to 26 °C and 44%, respectively.

Ethical Approval

The ethics and research committee granted approval for this study, and the ministry of agriculture in Edo State, Nigeria, provided ethical number V.1041/81.

Experimental Design

Over the course of 14 days, the right amount of *D. alata* extract was given to each animal through an orogastric tube after it was carefully picked out with a hand towel.

All that was given to Group I (the positive control) was food and purified water.

Group II (the negative control) was administered a single daily dosage of tramadol at a rate of 20 mg/kg.

Group III: a single *D. alata* dosage of 200 mg/kg

Group IV: 300 mg/kg of *D. alata* for the following seven days and 20 mg/kg of tramadol once daily for the first seven days.

Group V: 500 mg/kg of *D. alata* extract taken orally for 14 days and 20 mg/kg of tramadol once daily.

Take note:

Two (2) rats from each group were given chloroform anaesthesia by inhalation to end the experiment, and 24 hours following the last day of treatment, the rats were killed by fenestration. Using a sterile surgical blade, the gastrointestinal tract's oesophagus, stomach, duodenum, and rectum were removed from all experimental groups, including the control group.

Histology Sample Processing

Following a 24-hour fixation period, the tissues were cut at a depth of 3-5 mm for every organ.

After that, the tissues were cleaned, dehydrated, and saturated with melted paraffin wax in an automated tissue processor. An embedding machine assisted with the embedding process. To make serial ribbons, 3-5-micron tissue slices were cut in German mode with a digital (Hz) rotary microtome. Hematoxylin and eosin (H&E) staining procedures were used on the sections (Bieger *et al.*, 2013; Wasswa *et al.*, 2017; Omorodion *et al.*, 2021; Ibeh *et al.*, 2021; Omorodion *et al.*, 2021).

The Haematoxylin and Eosin (H&E) Protocols

The section was hydrated and immersed in water after being dewaxed with two changes of xylene. It was then stained with either Cole's hematoxylin (10 minutes) or Mayer's hematoxylin. (5min), The part was properly cleaned under running tap water, and it was temporarily separated in 1% acid alcohol. The portion was counterstained with eosin for three minutes after being blued for five minutes in Scott's water. Running tap water was used to wash the part until any remaining eosin was gone. The portion had varying degrees of alcohol-related dehydration (70%, 90%, and absolute). After being cleaned in xylene, the section was mounted in DPX (Bieger *et al.*, 2013; Wasswa *et al.*, 2017; Omorodion *et al.*, 2021; Ibeh *et al.*, 2021; Omorodion *et al.*, 2021).

Photomicrography and microscopy

A 400x Olympus photomicroscope® (Opticshot-2; Nikon, Tokyo, Japan) with white films and a Swift binocular microscope with an integrated lighting system were used to look at the sections.

Statistics Analytical

SPSS, a programme developed by IBM (Chicago, Illinois, USA), version 20.0, was used to analyse the data. The results of the study of the data were presented using means and SEM after one-way analysis of variance, or ANOVA, was employed. $P < 0.05$ was the significance threshold at which the Duncan post hoc test was used to evaluate pairwise differences between groups.

RESULTS

Acute Toxicity

At the highest dose level that was examined, 2000 mg/kg, neither fatalities nor adverse effects were reported (Maithili et al., 2011).

Table 1: Mean values of the weight of adult Wistar albino rats pretreated with Tramadol and *Dioscorea alata*.

Parameters	Group 1	Group 2	Group 3	Group 4	Group 5
Stomach weight (g)	1.400 ± 0.10	1.300 ± 0.10	1.100 ± 0.10*	1.300 ± 0.10	1.200 ± 0.20
Initial body weight (g)	131.5 ± 3.47	149.0 ± 0.82	129.5 ± 1.43	148.5 ± 1.02	147.5 ± 1.02
Final body weight (g)	158.0 ± 0.40	175.5 ± 1.84	145.5 ± 0.61	165.0 ± 2.86	169.0 ± 2.04

P < 0.05 indicates significant difference

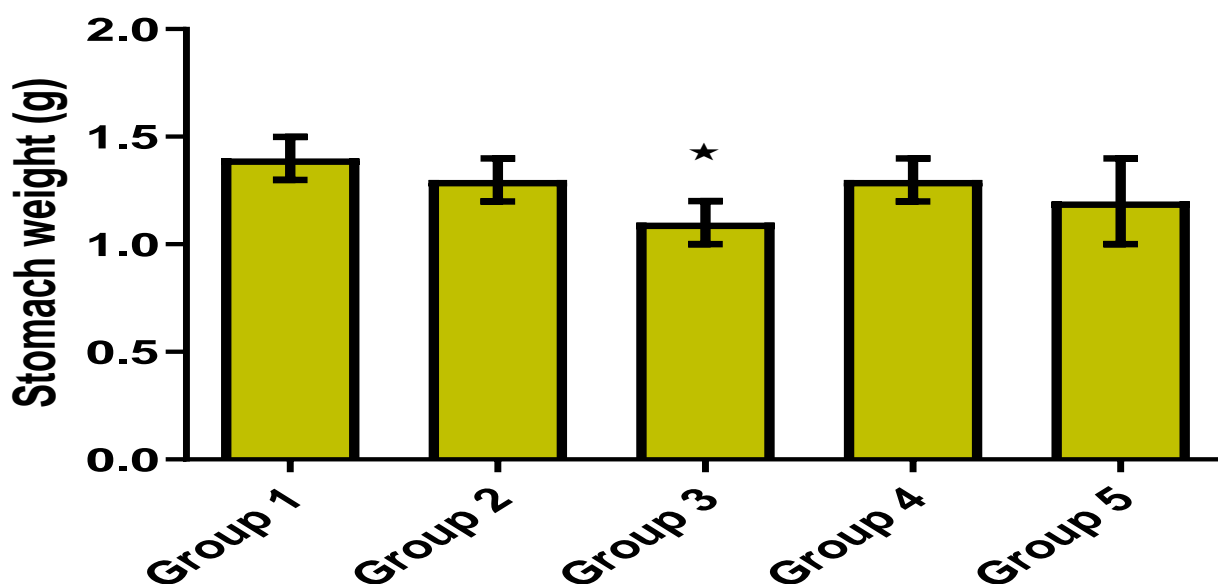


Figure 1: Effects of Tramadol and *Dioscorea alata* on the weight of stomach in adult Wistar rat

Group 3 showed a noteworthy decline when compared to group 1, while group 2, group 4, and group 5 showed no discernible variations when compared

Histological slides

In general, the size, consistency, and colour of the test and control organs differed. Atypical behaviour symptoms such as dullness, decreased activity, and restlessness were displayed by experimental rats, especially those in Group 2. All of the organs that were removed during grossing did not smell. Rats in groups 3 and 1 had significantly lower body

and organ (stomach) weights than rats in groups 2, 4, and 5, respectively, as the statistical table (4.1) illustrates. However, there were no significant differences between groups 2 and 1.

Histopathology and photomicrographs from positive and negative control rats were compared to those from the treated groups and are shown in (Plate 1-5).

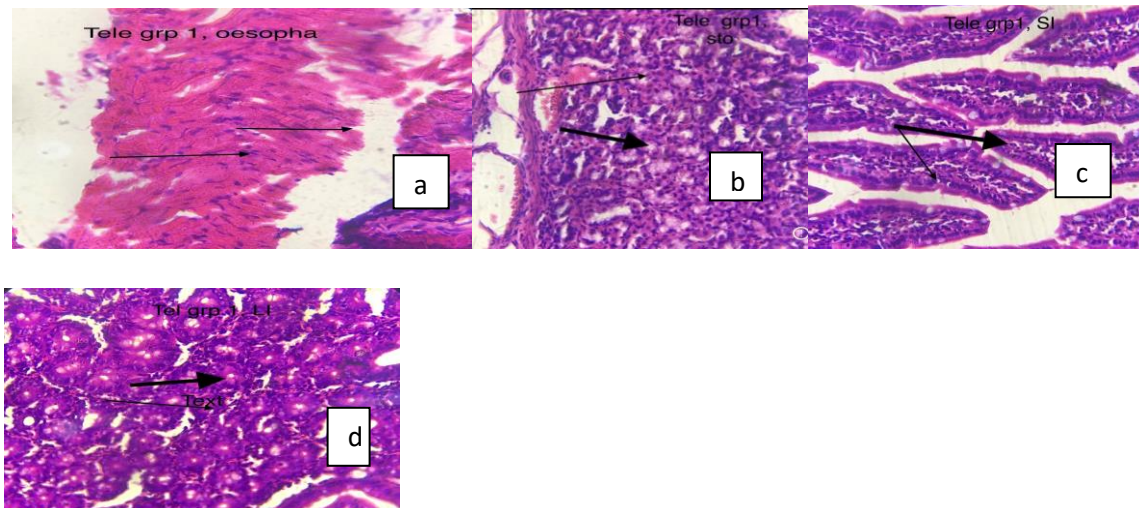


Plate 1: As a positive control, a photomicrograph of the tissue oesophagus of a rat given only food and distilled water shows normal mucosa and muscularis (arrows). displays a tissue stomach photomicrograph that was fed only food and distilled water, acting as a positive control with typical stomach pits and glands (arrows). shows a photomicrograph of a rat's small intestine with normal villi and goblet cells (arrows), serving as a positive control. It also shows a photomicrograph of a rat's large intestine with glands (arrows), also serving as a positive control. Both rats received only food and distilled water. H and E. X400MAG.

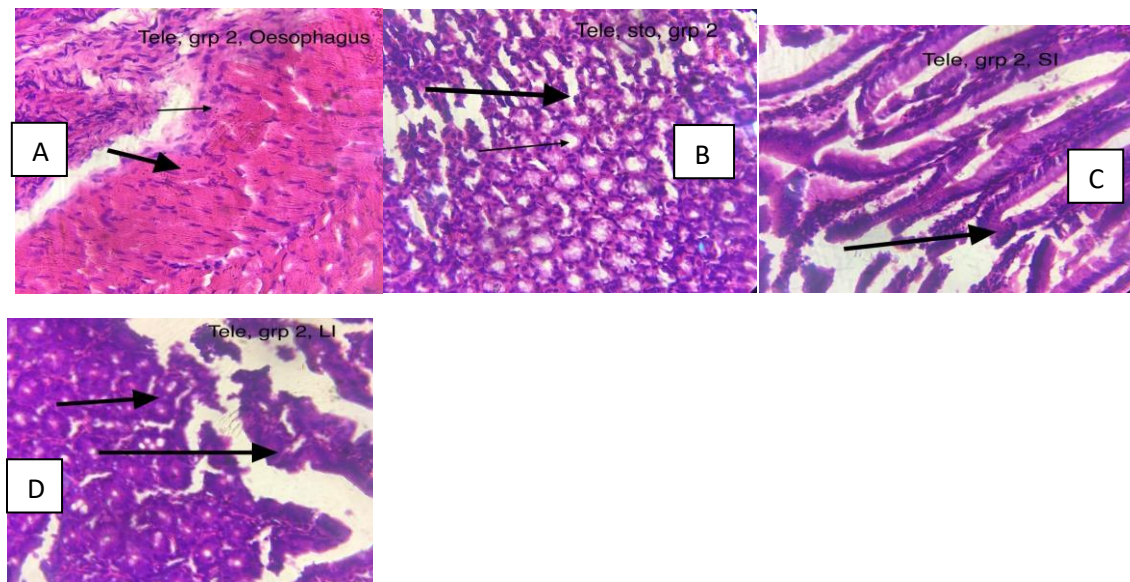


Plate 2: The tissue was administered a daily dosage of tramadol at a concentration of 20 mg per kilogramme. In this photomicrograph, a single daily dose of Tramadol at a concentration of 20 mg per kilogramme was employed as a negative control to observe the effects on stomach tissue with ulceration, specifically the inflammatory gastric pit and submucosa linings. A negative control was established using a single daily administration of 20 mg/kg of tramadol. This was demonstrated using photomicrographs of small intestinal tissue exhibiting inflamed villi and goblet cells. A negative control was established with a single daily administration of 20 mg/kg of tramadol. The photomicrographs revealed significant inflammation in the intestinal tissue, including the glands and goblet cells. Hematoxylin and eosin staining at a magnification of 400x.

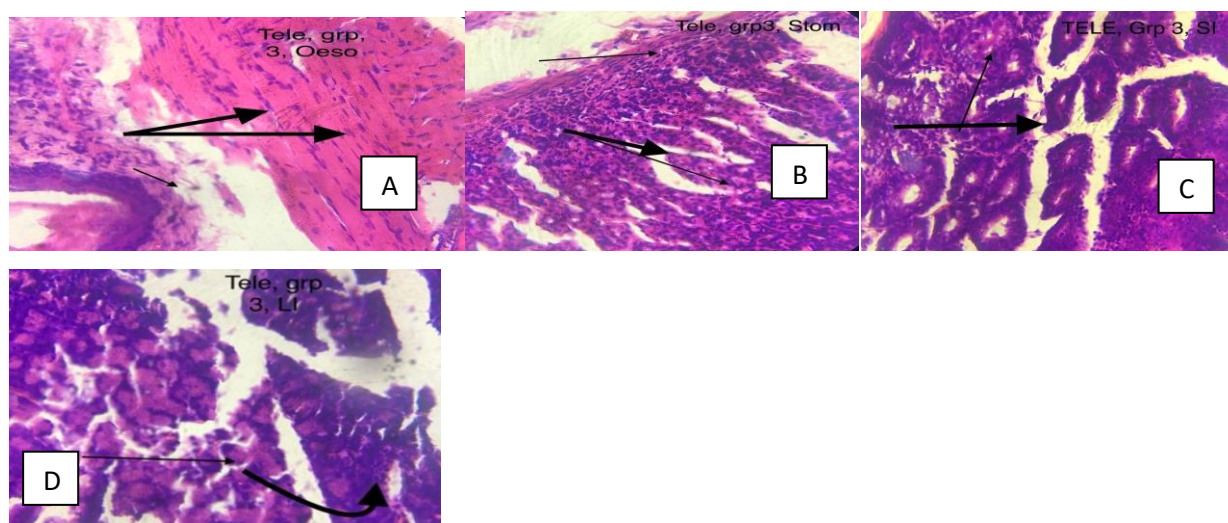


Plate 3: Displays a normal photomicrograph of oesophageal tissue with smooth muscle lining and stratified squamous epithelia after receiving a single 200 mg/kg dosage of *D. alata* (group 3). Photomicrograph of stomach tissue with normal stratified columnar epithelia is displayed; nevertheless, the gastric pits along the other mucosa sections, which were given a single dose of 200 mg/kg of *D. alata* (group 3), were somewhat inflamed. The third slide (C), displays a photomicrograph of the small intestinal tissues (group 3) that received a single 200 mg/kg dosage of *D. alata*, with somewhat inflamed villi along the other mucosa sections and submucosa area. Photomicrograph of large intestine tissues with somewhat inflammatory glands, mucosa areas, and submucosa of tissue area that received a single dosage of 200 mg/kg of *D. alata* (group 3). H and E. X 400 mag.

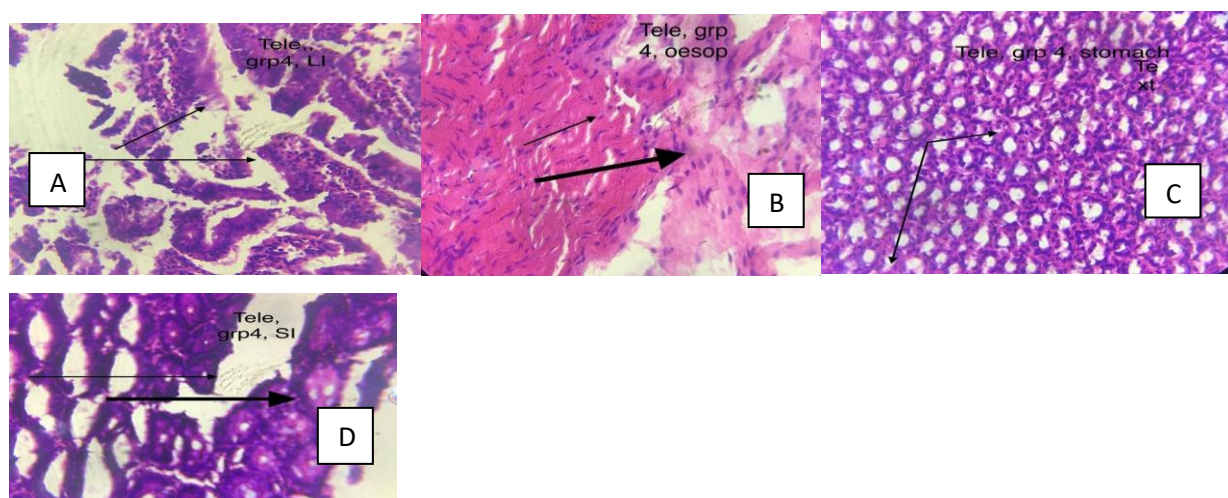


Plate 4: A photomicrograph of the GIT's esophageal tissue, demonstrating normal mucosal, lamina propria, and submucosal areas. The subject received a daily dose of tramadol (20 mg / kg) for the first seven days, followed by a 300 mg / kg dose of *D. alata* (group 4) for the next seven days (slide A). The fundus portion of the stomach (GIT) with normal gastric pits and glands (arrows) is shown in a photomicrograph (slide B), which received 300 mg/kg of *D. alata* (group 4) and 20 mg / kg of tramadol once daily for the first seven days. Slide C, shows distal portion of the small intestine tissue (GIT) with normal glands and goblet cells (arrows) and were given 300 mg/kg of *D. alata* (group 4) and 20 mg / kg of tramadol once daily for the first seven days. Slide D is a photomicrograph of the proximal portion of the large intestine tissue (GIT) with normal lieberkuhn crypts, panel cells, and glands (arrows), were given 300 mg/kg of *D. alata* and 20 ml/kg of tramadol once daily for the following seven days. X 400mag. H. and E.

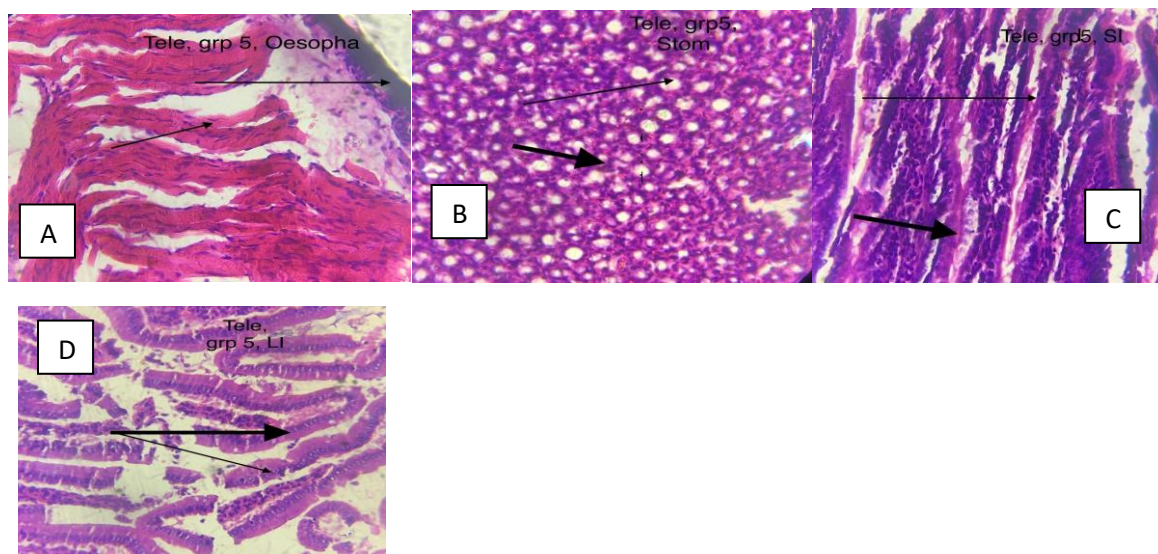


Plate 5: A photomicrograph of a normal submucosal, lamina propria, and muscularis (arrows) after 14 days of oral administration of 500 mg / kg of *D. alata* extract and 20 mg / kg of tramadol once daily (slide A). Slide B shows photomicrograph of stomach architecture like gastric pits and goblets cells seeming normal (arrows) which were fed oral dose of 500 mg/kg of *D. alata* extract for 14 days and 20 mg / kg of tramadol once daily. Slide C, display a photomicrograph of small intestine tissue that was given oral *D. alata* extract at a dose of 500 mg/kg for 14 days and 20 mg/kg of tramadol once daily, the architecture of the villi and goblets cells appears normal (arrows). Photomicrograph of large intestine tissue (slide D) showing architectures such as crypts lieberkuhn, panel cells, and goblets cells appearing normal (arrows) after 14 days of oral administration of 500 mg/kg of *D. alata* extract and 20 mg/kg of tramadol once daily. H and E. X 400 mag.

DISCUSSION

Tramadol inflames the gastrointestinal tracts of group 2 rats, according to the current investigation. Nevertheless, it was shown that *D. alata* helped to reduce some of these inflammations and changes in tissue architecture. Once more, it is possible that the mild inflammatory cells observed in the gastrointestinal tract of rats in group 3, who were given only *D. alata*, resulted from inflammation and defence mechanisms against the alien substances. Although inflammatory response processes depend on the precise nature of the initial stimulus and its location in the body, they all share a common mechanism, which can be summarised as follows: 1) cell surface pattern receptors recognise detrimental stimuli; 2) inflammatory pathways are activated; 3) inflammatory markers are released; and 4) inflammatory cells are recruited (Libby, 2007).

Notable researchers like Sagata *et al.* (2002) have demonstrated in their work that tramadol-induced inflammation of the cellular component of the GIT is not new. They found that atropine replaces (14C)-tramadol bound to adrenal medullary cells, indicating that tramadol affects muscarinic receptors in a competitive manner. Additionally, tramadol stops the function of M1 and M3 receptors by binding to quinuclidinyl benzilate (QNB) sites at levels that are clinically significant (Shiraishi *et al.*, 2001; Shiga *et al.*, 2002). The current finding, which is in line with previous data, indicates that tramadol causes inflammation in the stomach region (group 2) (Shiraishi *et al.*, 2001; Minami *et al.*, 2004) through tramadol's pH-raising action in the stomach. In group 3, the amount of pH increase in the stomach was not observed to be dose-dependent. Due to the intravenous method used to administer tramadol, Minami *et al.* (2004) and Elhakim *et al.* (2005) started measuring the stomach pH earlier in their investigations. After 50 mg of intramuscular tramadol, the maximum plasma concentration was measured at 166 ng/ml 45 minutes after injection; the similar value for the intravenous dose was 293 ng/ml 30 minutes after injection (Elhakim *et al.*, 2005). They found that the pH levels were much higher than baseline. If they had waited a lot longer before testing the stomach pH, it is possible that larger results would have been achieved (Elhakim *et al.*, 2005).

Dioscoreaceae alata's ameliorative qualities may be attributed to a variety of phytonutrients found in the plant, including phenols, flavonoids, saponins, anthocyanins, carotenoids, and water-soluble polysaccharides (Dooney *et al.*, 2014; Elhakim *et al.*, 2005). Numerous ailments, including hypertension, asthma, abscesses, chronic diarrhoea, diabetes, inflammation, cancer, and ulcers, have been treated with it in Asian traditional medicine. It has also been widely used to enhance health (Ying-Yang and Jia Yin (2018); Miyoshi *et al.* (2011; Chen *et al.* (2014; Padhan and Panda (2020; Lebot *et al.* (2023). Yam additionally increases intestinal Na⁺/K⁺ATPase activity by activating imidazoline I-2 receptors, as demonstrated by the findings of McAnuff *et al.* (2005) and Lin *et al.* (2012).

According to the study conducted by Laine *et al.* (2008), the ethanol extract of *Dioscoreae* meat may possess anti-inflammatory and antioxidant characteristics. In addition, it may stimulate the formation of prostaglandin E₂ (PGE₂), a substance that protects the stomach lining, as found in groups 4 and 5. Group 4 provided evidence that PGE₂ activates prostaglandin E receptors, leading to several beneficial effects such as promoting gastric mucus secretion, increasing blood flow to the mucosal lining, protecting mucosal cells from cell death, and accelerating the healing of wounds and the mucosal lining. Administration of ethanol decreases the amount of PGE₂ in the stomach mucosa (Wallace, 2008; Zhao *et al.*, 2009; Takeuchi and Amagase, 2018). Consistent with previous research, it was found that ethanol infusion decreased the concentration of the PGE₂ protein in the stomach homogenate. The gastroprotective effect of the DBD extract was partially attributed to PGE₂. However, the PGE₂ level was significantly restored when the subjects were treated with water or ethanol extracts of either *Dioscorea* flesh or peel (Wallace, 2008; Zhao *et al.*, 2009; Takeuchi and Amagase, 2018).

CONCLUSION

Rats exposed to tramadol showed improved gastrointestinal tract function after consuming extracts of *Dioscorea alata*. This might be explained by the bioactive substances that have anti-inflammatory, antioxidant, and gastrointestinal-protective qualities found in the peel of water yams. *Dioscorea alata* may be used as a natural medicine to shield the gastrointestinal system from the harmful effects of tramadol, as demonstrated by our findings, which were supported by the alleviative effects seen in the histological study and biochemical indicators.

RECOMMENDATION

The present work lays the groundwork for further research on *Dioscorea alata* as a possible adjunctive or substitute strategy to lessen the gastrointestinal tissue damage caused by tramadol. Though the results are encouraging, it's crucial to remember that more investigation is required to confirm the findings, clarify the underlying mechanisms causing these effects, examine dosage concerns, and assess the treatment's long-term impacts.

REFERENCES

- Asumugha, G. N., Njoku, M. E., Okoye, B. C., Aniedu, O.C., Ogbonna, M.C., Anyaegbunam, H.N., Akinpelu, O. A., Ibeagi, O. and Amaefula, A. (2009). An analysis of the supply for seed yams in Nigeria. *African Journal of Business Management*, **3**(1): 028-031.
- Bhandari, M. R., Kasai, T. and Kawabata, J. (2003). Nutritional evaluation of wild yam (*Dioscorea* sp.) tubers of Nepal. *Food Chemistry*, **82**(4): 619–623.
- Bieger, D., Hopkins, D.A., Dickman, C.A., Fessler, R.G. and Sekhar, L.N. (2013). Anatomy of the Swallowing Mechanism. *Surgery of the Craniovertebral Junction*, 149-159. DOI: [10.3171/2015.1.FOCUS14807](https://doi.org/10.3171/2015.1.FOCUS14807)

- Chen, M.F., Tsai, J.T., Chen, L.J., Wu, T.P., Yang, J.J., Yin, L.T., Yang, Y.L., Chiang, T.A., Lu H.L. and Wu, M.C. (2014). Antihypertensive action of allantoin in animals. *Biomedical Research International*, **5**(2):12-15. DOI: [10.1155/2014/690135](https://doi.org/10.1155/2014/690135)
- Dooney, N.M., Sundararajan, K., Ramkumar, T., Somogyi, A.A., Upton, R.N., Ong, J., O'Connor, N.S., Chapman, M.J. and Ludbrook, G.L. (2014). Pharmacokinetics of tramadol after subcutaneous administration in a critically ill population and in a healthy cohort, *Bio Medical Central Anaesthesiology*, **14**: 33. DOI: [10.1186/1471-2253-14-33](https://doi.org/10.1186/1471-2253-14-33)
- Elhakim, M., Abd El-Megid, W., Metry, A., El-hennawy, A. and El-Queseny, K. (2005). Analgesic and antacid properties of i.m. tramadol given before Caesarean section under general anaesthesia. *British Journal of Anesthesia*, **95**:8-115. DOI: [10.1093/bja/aei260](https://doi.org/10.1093/bja/aei260)
- Fu, Y.C., Huang, P. Y. and Chu, C. J. (2005). Use of continuous bubble separation process of separating and recovering starch and mucilage from yam (*Dioscorea pseudojaponica* Yamamoto). *Food Science Technology*, **38**(7): 735–744. doi: [10.3390/polym14153142](https://doi.org/10.3390/polym14153142)
- Ibeh, N.I., Omorodion, N.T., Moses-Otutu I.M., Okungbowa, M.A. (2021). ‘Studies on the in-Vitro Haematoxicity of *Vernonia amygdalina* Leaf Extract on Human Erythrocyte’. *World Journal of Biomed Research*, **8**(1):30-35
- Laine, L., Takeuchi, K. and Tarnawski, A. (2008). Gastric mucosal defense and cytoprotection: Bench to bedside. *Gastroenterology*, **135**:41–60. DOI: [10.1053/j.gastro.2008.05.030](https://doi.org/10.1053/j.gastro.2008.05.030)
- Lebot, V., Lawac, F. and Legendre, L. (2023). The Greater Yam (*Dioscorea alata* L.): A Review of Its Phytochemical Content and Potential for Processed Products and Biofortification. *Journal of Food Composition and Analogy*, **115**:104-987. DOI: [10.1016/j.jfca.2022.104987](https://doi.org/10.1016/j.jfca.2022.104987)
- Libby, P. (2012). Inflammatory mechanisms: the molecular basis of inflammation and disease. *Nutritional Revolution*, **65**: S140–S146. DOI: [10.1111/j.1753-4887.2007.tb00352.x](https://doi.org/10.1111/j.1753-4887.2007.tb00352.x)
- Lin, K.C., Yeh LR., Chen, L. J., Wen, Y.J., Cheng, K.C. and Cheng, J. T. (2012). Plasma glucose-lowering action of allantoin is induced by activation of imidazoline I-2 receptors in streptozotocin-induced diabetic rats. *Hormonal Metabolic Research*, **44**:41–46. DOI: [10.1055/s-0031-1295439](https://doi.org/10.1055/s-0031-1295439)
- Maithili, V., Dhanabal, S.P., Mahendran, S. and Vadivelan, R. (2011). Antidiabetic activity of ethanolic extract of tubers of *Dioscorea alata* in alloxan induced diabetic rats. *Indian journal of pharmacology*, **43** (4): 455. doi: [10.4103/0253-7613.83121](https://doi.org/10.4103/0253-7613.83121)
- McAnuff, M.A., Harding, W.W., Omoruyi, F.O., Jacobs, H., Morrison, E.Y. and Asemota, H.N. (2005). Hypoglycemic effects of steroidal sapogenins isolated from jamaican bitter yam, dioscoreapolygonoides. *Food Chemistry Toxicology*, **43**:1667–1672. DOI: [10.1016/j.fct.2005.05.008](https://doi.org/10.1016/j.fct.2005.05.008)
- Minami, K., Ogata, J., Horishita, T., Shiraishi, M., Okamoto, T. and Sata, T. (2004). Intramuscular tramadol increases gastric pH during anesthesia. *Canada Journal of Anaesthesiology*, **51**:54 - 58. DOI: [10.1007/BF03018395](https://doi.org/10.1007/BF03018395)
- Miyoshi, N., Nagasawa, T., Mabuchi, R., Yasui, Y., Wakabayashi, K., Tanaka, T. and Ohshima, H. (2011). Chemoprevention of azoxymethane/dextran sodium sulfate-induced mouse colon carcinogenesis by freeze-dried yam sanyaku and its constituent diosgenin. *Cancer Preview Research*, **4**:924–934. DOI: [10.1158/1940-6207.CAPR-10-0279](https://doi.org/10.1158/1940-6207.CAPR-10-0279)
- National Institute of Diabetes and Digestive and Kidney Diseases (NIDDK) (2017). Available at: 2017, <https://www.niddk.nih.gov>. Accessed: 3rd May, 2023.
- Nwaoguikpe, R.N. (2009). The anti-sickling effects of some edible vegetables, *International Journal of Biological and Chemical Science*, **3**(5): 1005-1012. DOI:[10.4314/ijbcs.v3i5.51079](https://doi.org/10.4314/ijbcs.v3i5.51079)
- Omorodion, N.T., Aloho, H. and Achukwu, P.U. (2021). ‘Sub-acute Effects of Isoniazid (Inh) on The Kidney and Liver of Albino Mice’. *International Journal of Basic Science and Technology*, **7**(1):10 – 14.
- Omorodion, N.T., Aniobi C C., Achukwu, P.U. and Nwibana, B.K. (2021). ‘Hepatocellular and renal effect of *Gongronema latifolium* leaf extract on Albino rat following acetylamino phen (Paracetamol) poisoning’. *Nigerian Journal of Pharmaceutical and Applied Science Research*, **10**(2): 21-27.
- Omorodion, N.T., Aniobi, C.C., Abdumini, L.M. and Achukwu, P.U. (2021). ‘Prevalence of Papillary and Follicular Thyroid Carcinoma in Patient Who Visited University of Nigeria Teaching Hospital (UNTH) (2014 – 2018)’. *International Journal of Basic Science and Technology*, **7** (1):15 – 19.
- Owoade, A.O., Adetutu, A. and Olorunnisola, O.S. (2019). Hematological and Biochemical Changes in Blood, Liver and Kidney Tissues under the Effect of Tramadol Treatment. *Journal of Alcohol Drug Depend*, **7**: 327
- .Padhan, B. and Panda, D. (2020). Potential of Neglected and Underutilized Yams (*Dioscorea* spp.) for Improving Nutritional Security and Health Benefits. *Frontial Pharmacology*, **11**:496. doi.org/10.3389/fphar.2020.00496
- Sagata, K., Minami, K., Yanagihara, N., Shiraishi, M., Toyohira, Y. and Ueno, S. (1992). Tramadol inhibits norepinephrine transporter function at desipramine-binding sites in cultured bovine adrenal medullary cells. *Anesthesia Analgesics*, **94**:901–906. DOI: [10.1097/00000539-200204000-00024](https://doi.org/10.1097/00000539-200204000-00024)
- Shiga, Y., Minami, K., Shiraishi, M., Uezono, Y., Murasaki, O., Kaibara, M. and Shigematsu, A. (2002). The inhibitory effects of tramadol on muscarinic receptor-induced responses in *Xenopus* oocytes expressing cloned M3 receptors. *Anesthesia Analgesics*, **95**(12): 69–73. DOI: [10.1097/00000539-200211000-00031](https://doi.org/10.1097/00000539-200211000-00031)

- Shiraishi, M., Minami, K., Uezono, Y., Yanagihara, N. and Shigematsu, A. (2001). Inhibition by tramadol of muscarinic receptor-induced responses in cultured adrenal medullary cells and in *Xenopus laevis* oocytes expressing cloned M1 receptors. *Journal of Pharmacological Experiments and Therapy*, **299** (2) 55–60.
- Takeuchi, K. and Amagase, K. (2018). Roles of Cyclooxygenase, Prostaglandin E2 and EP Receptors in Mucosal Protection and Ulcer Healing in the Gastrointestinal Tract. *Current Pharmacological Disease*, **24**:2002–2011. DOI: 10.2174/1381612824666180629111227
- Tørring, M.L., Riis, A, Christensen, S., Thomsen, W.S., Jepsen, P., Jens Søndergaard, J. and Sørensen, H.T. (2008). Perforated peptic ulcer and short-term mortality among tramadol users, *British Journal of Clinical Pharmacology*, **65**(4):565-72. DOI: 10.1111/j.1365-2125.2007.03038.x
- Wallace, J.L. (2008). Prostaglandins, NSAIDs, and gastric mucosal protection: Why doesn't the stomach digest itself? *Physiology Review*, **88**:1547–1565. DOI: 10.1152/physrev.00004.2008
- Wasswa, J.N., Avwioro, G.O. Omorodion, N.T. and Asimiyu, O.S. (2017). Histological effect of Piper guineense (UZIZA) leaves on the liver of wistar rats. *International Journal of Research and Review*, 4(3): 36 – 41.
- Wireko-Manu, F.D., Oduro, I., Ellis, W.O., Asiedu, R. and Mazi-Dixon, B. (2013). Potential health benefits of water yam (*Dioscorea alata*). *Food and Function* **4**(10): 1496-1501. Doi: 10.1030/c3fo60064e.
- Ying-Yang, X. and Jia Yin (2018). Identification of a thermal stable allergen in yam (*Dioscorea opposita*) to cause anaphylaxis, *Asia Pacific Allergy*, **8**(1): e4. doi: 10.5415/apallergy.2018.8.e4
- Zhao, W., Zhu, F., Shen, W., Fu, A., Zheng, L., Yan, Z., Zhao, L. and Fu, G. (2009). Protective effects of DIDS against ethanol-induced gastric mucosal injury in rats. *Acta Biochimistry and Biophysiology Sin (Shanghai)*, **41**(4):301-308. doi: 10.1093/abbs/gmp014